



SPOCUS

The Society of Point of Care Ultrasound

The Echo Chamber

The Official Newsletter of the Society of Point-of-Care Ultrasound



Fall
2019

FROM THE PRESIDENT

Headed back from [WCUME19](#) with some fresh ideas and perspectives. The conference perennially attracts the biggest names in #POCUS, so it was hard to not be star-struck walking amongst the giants in the field. It was also exciting to see the innovative ways ultrasound is improving medical education and how that education is improving medical care. The organizers, led by Dr. Chris Fox, put on an outstanding conference. Highlights include Dr. Cindy Bennett's work (below) integrating



ultrasound and illustrative anatomy to better demonstrate human anatomy, and Brian Ahern's case report, which is featured on page 7 of this newsletter.

Despite the fact that [SPOCUS was well-represented in the oral abstract sessions at WCUME](#), there was a

distinct lack of time dedicated to discussions on the use of POCUS outside of the physician profession. We all know that healthcare is a team-sport. Physician-led teams are proven to improve healthcare, and so is POCUS. But POCUS employment isn't limited to physicians. I was curious as to why there wasn't more presentations dedicated to the nuances of POCUS employment by others on the healthcare team. Sure, sonographers were represented, but what about APPs? Or nurses? PTs? Medical techs? EMS personnel? The versatility of POCUS lends itself to employment across various practice scopes and educational settings, but are physician-leaders promoting and guiding POCUS employment by other team members? Are they growing and positively influencing non-physician POCUS leaders? I couldn't help but feel that there was an emerging but still-unrealized opportunity for collaboration. (cont page 2)

IN THIS ISSUE...

- *Learn about new, SPOCUS-sponsored scholarship opportunities*
- *Hear one member's experience with a POCUS mini-fellowship*
- *MSK POCUS Guru Member Erica Miller-Spears is featured in our Member Spotlight*
- *POCUS Case Report – pediatric respiratory distress*
- *New crowdsourced SPOCUS presentation library*

....and much more!

Perhaps the problem lies with us? Despite the great work that our members and others are doing with POCUS education, when we fail to share that great work, others lose out. As an introvert, I know first-hand how easy it can be to comfortably remain inside your own bubble. So, I call on those who are innovatively expanding POCUS employment and education to socialize your experiences and work with others who are hungry for new methods. My hope is that WCUME20 will feature the variety of educational realms in which POCUS is being employed...and in doing so, will create thoughtful discourse and interprofessional collaboration which creatively and collegially overcomes the emerging challenges that are being generated from increasingly widespread availability of ultrasound.

-Jonathan Monti, PA-C




CPT Brian Ahern, DSc, PA-C (left) presents a case of pediatric pneumonia, and CPT Roland Salazar, PA-C (right) presenting his research comparing medic performance with handheld US devices at the World Congress of Ultrasound in Medical Education 2019

Now Accepting Board of Director Nominations!

Interested in helping to lead a rapidly-growing organization? Are you a talented thought-leader who welcomes challenges and fosters multilevel collaborative opportunities? SPOCUS is now accepting nominations for the following Board Positions:

- President-Elect
- Director-at-Large (2 positions)
- Social Media Director
- Secretary - Treasurer

Nominations are due by 15 October. An email with nomination form will be sent soon. Self-nominations will be accepted. We also have committee leadership position opportunities available. Send inquiries to spocus001@gmail.com



A PA's POCUS MINI-FELLOWSHIP EXPERIENCE

The following details the experience of Patrick Bafuma and his experience with a POCUS Mini-Fellowship. (reprinted with permission from EMinFocus Blog)

Are you looking for a bridge after taking an ultrasound course at a conference? Do you feel like you need a bit more oversight until you get comfortable with probe in hand? Are you having trouble conceptualizing what it means to have ultrasound guide your practice in the critically ill?

I recently had the pleasure of attending a [CCUS POCUS mini-fellowship](#) – it was everything I was hoping for & more- and has pushed me to be a better clinician.

First, a blurb about ultrasound fellowships. As a PA, there isn't really any hands-on US training during our programs. There likely is some POCUS for PA EM residents – but most practicing EM PA's are not residency trained. Therefore, we're at the mercy of our co-workers who may (or may not) have any US training. It's hard to learn POCUS when you don't have someone over your shoulder to guide you!

I had done a few ultrasound courses, but was struggling to really implement it into my practice regularly. Ultimately, this was my own fault. I was repeatedly told to pick up the probe and practice. Literally, every sono-savvy person has told me this. A large part of my problem was that I did not pick up the probe immediately after courses to drill down on fundamentals – and scan every person regardless of their complaint. This is not meant to disrespect those that I took courses with before – they were *extremely* helpful and I'm incredibly thankful for their expertise! – the fact that I continued to seek out ultrasound training is a testament to prior courses showing me the importance of developing this tool set. Now, onto Canada.

I ended up taking a 2 day course with [Philippe Rola](#) in Montreal. Philippe is extremely responsive via email, we had spoken on the phone a few times prior to my arrival as well. He's friendly, approachable, and has been doing mini-fellowships since 2009.

I was looking to optimizing views, particularly on patients with challenging anatomy (I mean, have you seen the average American BMI recently?), and what started with, “where the hell is the IVC” turned into, “This is a plethoric IVC.” While it might be that the 3rd (or is it 4th?) time is the charm for courses for me, and that I would get it eventually via spaced repetition, but there is something about practicing on patients with acute illness and watching Rola make decisions based on POCUS in real time that helps put the pieces together a bit faster.

I believe the main advantage of this US course is the real time feedback on real patients... and if you are there for more than one day, you get to watch the ICU story unfold. You see about 10-12 patients in their ICU, and a handful of ICU consults on the floors or in the ED. You may or may not

“...the main advantage of this US course is the real time feedback on real patients...”

What we've been up to....

- Collaborating with ACEP to define an EUS credentialing pathway for APPs
- Strategy development for increasing POCUS fellowship opportunities
- Collaborating with AIUM for APP inclusive POCUS training guidelines
- New partnership with 7D imaging
- National-level resolution to recognize POCUS as skill integral to the practice of medicine

go to a rapid response, and see how it really makes a difference in the heat of the moment. Fortunately, this is not reminiscent of your student days when the mentor says, “You’ll have to sit this out, this one’s mine, sorry.” Philippe was extremely patient with me in the hypotensive altered patient while I scanned. He’s excellent at questioning at just the right time to help tie it together- “ok, what are you seeing? A plump IVC and some pleural effusions in this hypotensive patient? So what’s your next step?”

To maximize your experience, I would strongly encourage you to have 1-2 specific goals in mind like, “I want be able to consistently visualize the IVC and have a few back up views just in case.” Expecting more than 1-2 things is probably spreading yourself thin. You’re not going to become a pro overnight. Be upfront & honest with Rola – he can tailor to your skill level- whether it be an assessment of valvular function or just wanting to visualize the heart. Philippe had recommended 2-3 days at a time, which I agree with – I think after 2-3 days you reach the point of diminishing returns and “get full.” You need some time to process what you’ve learned, and to practice on your own (before going back!).

Upon my return home, I made it a point to utilize the probe on my next shift. If at all possible, I would recommend arranging shifts to be “main ED” shifts when you get back home such that you see the belly pain, shortness of breath, and chest pain patients so that you can apply what you learned immediately. I did this on my first shift back with the hope of scanning 5 patients or more – I literally brought the machine with me when I walked into the room. Surprisingly, I thought it would slow me down. This was not the case at all. I also realized a major benefit that I was not expecting. The cognitive offloading of using the probe and eliminating some of the guess work kept me fresher longer. I saw more patients than average, with sicker than average patients, and it did not feel like taxing shift at all. I didn’t have to task switch to check on that xray or CT nearly as much as I usually do (though I was still ordering what I usually would to confirm suspicions since I’m still early in POCUS training)... I would be interested to see the throughput of docs using POCUS vs those not, and I’d also like to see the level of “decision fatigue” at the end of a shift – I’m convinced that POCUS provides a significant cognitive offload to the EM provider, and the POCUS’ers are less fatigued at the end of their shift.

Bottom line, I think I needed other courses to whet my appetite and open the door, and I needed Montreal to push me through the door and get me to start practicing more. If you work in an environment where you don’t have much POCUS backup and want to learn with one of the best and don’t want to break the bank, come to Montreal!

Have you completed a mini-fellowship or know of any opportunities to do so? We’d love to hear from you at SPOCUS001@gmail.com

New SPOCUS Presentation Repository!

We’ve created an easy-to-access [library of presentations](#) that educators can use to present important didactic concepts. In the generous spirit of SPOCUS, our intent is to allow members to use these resources as needed, and hope they they share improved versions or new presentations.

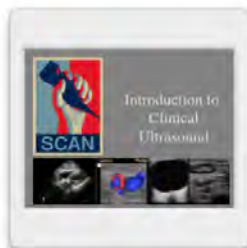Democratizing POCUS would be impossible without you!



Basic Physics and Instrumentation...or SPOCUS.pptx



Focused Cardiac Echo FoCUS - SPOCUS.pptx



Intro to Clinical Ultrasound SPOCUS.pptx



Quick eFAST_AO_DVT SPOCUS.pptx

MEMBER SPOTLIGHT

Erica Miller-Spears PA-C, ATC, RMSK is a faculty-member at the Southern Illinois University PA Program. She dazzled students with her MSK skills at this year's AAPA iScan competition.

1) How did you get interested in POCUS? How has this changed your practice?

I graduated from PA school almost 12 years ago. The practice I started with and am still with today is part of a family medicine residency, sports medicine fellowship, associated with a PA program and is focused sports and occupational medicine. The physician I collaborate with was very interested in musculoskeletal ultrasound when I started but it took me a couple years to “get the ultrasound bug”. I attended a focused shoulder ultrasound course by Dr. Buford and Dr. DuBois and I was hooked from there. I have attended several other focused musculoskeletal courses over the years but did a lot of independent learning with books and scanning students and sports medicine fellows. About 5 years ago, the medical school and PA program were looking into incorporating POCUS into the education programs and my musculoskeletal ultrasound skills allowed me to transition into a new role with teaching medical students, residents, faculty, and PA students on uses of ultrasound in family medicine and musculoskeletal medicine. I again did a lot of independent reading, learning, and practicing POCUS and expanding beyond MSK ultrasound.

“Ultrasound continues to be the wave of the future in all areas of medicine...I believe all medical and PA programs will have this incorporated in training in the very near future.”

2) What applications do you use a lot? What about ones you want to learn?

I use ultrasound daily as an extension of my physical exam for many musculoskeletal problems.

Our main focus is diagnostic ultrasound that helps guide our treatment plan for the patient whether it is to pursue physical therapy, order further imaging, or referral to another specialist. Many times I use ultrasound to help educate a patient about their specific problem. I also use ultrasound for guided injections such as trigger fingers, De Quervains tenosynovitis, and glenohumeral joint steroid injections. I would like to learn more about and become more confident in nerve evaluation, findings on ultrasound, and possibly use ultrasound for nerve decompression one day.

3) Have you encountered barriers to doing more POCUS exams?

I have been very blessed and fortunate that I entered a practice where the physician had already been doing quite a bit of ultrasound in his practice. He was a pioneer and paved the way so to say. He is very pro PA and continues to be a mentor in this area. There was resistance from the hospital group and radiology group initially and still periodically there will be questions about our uses and processes. Being part of an academic institution has helped and the administration has been supportive on the education side.

4) We know you are quite adept at all things musculoskeletal - what would you say to someone wanting to learn how to use ultrasound in this setting?

Attending one course to get the ultrasound basics, learning a little about knobology (how the machine works), and lots and lots of hands on scanning. Start with scanning each patient you see with a shoulder problem. Let them know that you are learning about a new technique and you want to see what you can see. Learning the shoulder is probably the hardest joint in musculoskeletal ultrasound but once you get that down, all the other areas will make sense.

5) Can you think of three pearls for musculoskeletal ultrasound?

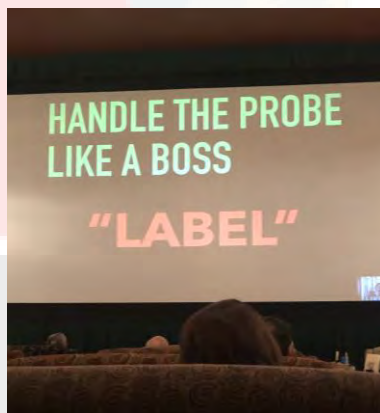

1. I have to echo the comment made by Jeremy, CRNA in the last member spotlight issue, “Know your anatomy”. This is the most important thing in musculoskeletal ultrasound as well.
2. Practice, Practice, Practice. Scan everyone you have access to. Nurses, coworkers, students, and all patients who are willing. The more you run through all the views and see lots of normals, the more likely you are to identify pathology.
3. Start with the shoulder, learn the anatomy and the scan protocol and once you master that one the other musculoskeletal scans will make sense.

6) Anything else you'd like to say to the general membership or students/faculty in particular?

Ultrasound continues to be the wave of the future in all areas of medicine. We are promoting it among the students and they are taking off with it. I believe all medical and PA programs will have this incorporated in training in the very near future. It is very satisfying for both provider and patient to see a problem in real time, confirm what you suspected with your exam, and help guide treatment or even treat a problem at the same visit.

Inaugural SPOCUS Scholarship Supports Workshop Attendance

Jessi Thorington was the winner of our inaugural SPOCUS scholarship. With the support of her scholarship award, she was able to attend the three-day [BendFest Ultrasound Workshop](#) in Oregon, earning 25 CME hours at a course with a great student:instructor ratio which maximizes hands-on scanning. Stay tuned for this year’s scholarship announcement!



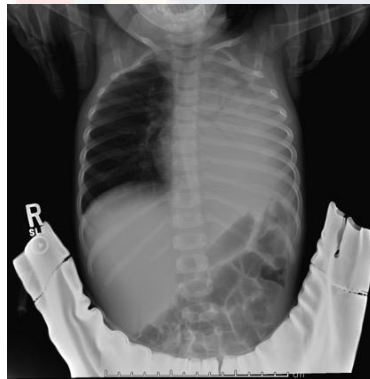
“...the amount of ultrasound genius crammed into that venue was incredible...I am so happy to be a part of an organization that believes in supporting education and networking for its members...”

Pediatric POCUS Case

This cool case comes to us from CPT Brian Ahern, PA-C, who is currently serving as an emergency ultrasound fellow at Madigan Army Medical Center. (originally presented at WCUME 2019)

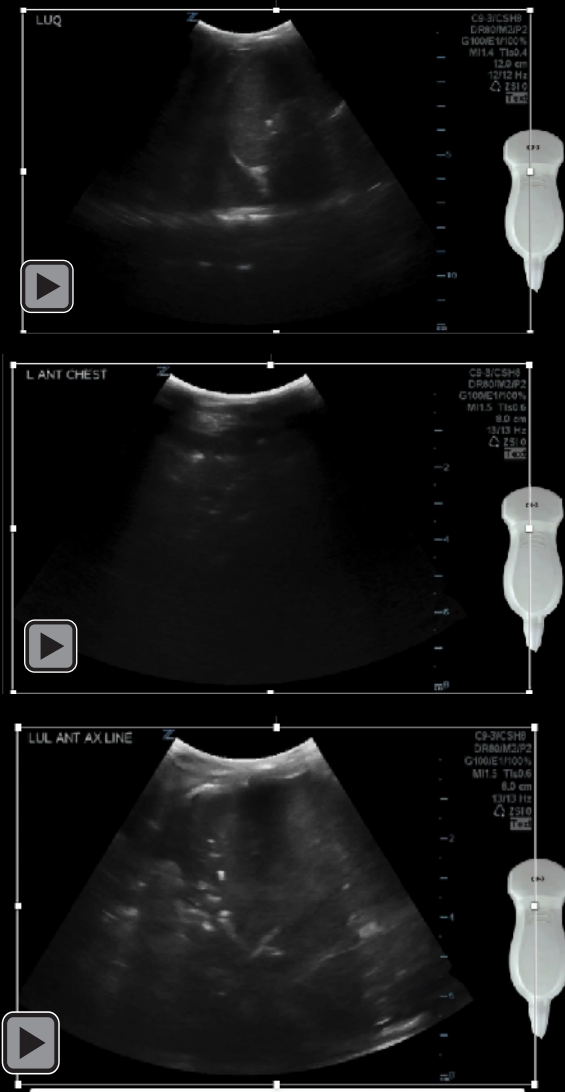
A previously healthy 2 y/o female that presented to a family medicine clinic with her mother for a fever and non-productive cough for 3 days in the setting of upper respiratory symptoms for 1 week.

- Her max temp was 39.4 C or 103F
- In clinic the patient was noted to have an increased work of breathing with diminished breath sounds in the left chest.
- She was sent to your emergency department for further evaluation.
- **Temp:** 36.5° C
- **HR:** 172 (80-130)
- **BP:** 98/46
- **RR:** 46 (20-30)
- **O₂sat:** 92% RA

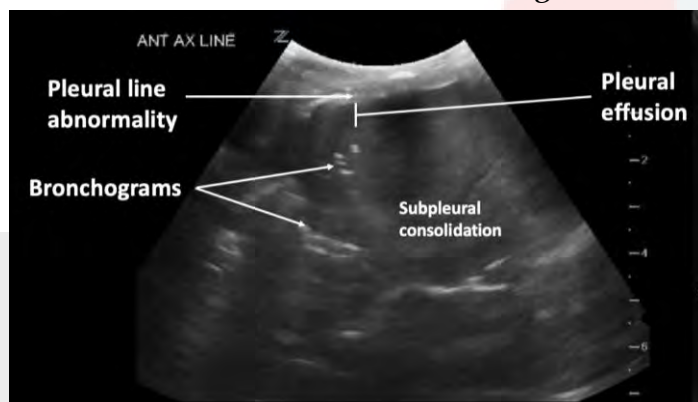


CXR shows opacified left hemithorax with DDX to include large consolidation, effusion, mass, or atelectasis

POCUS Findings

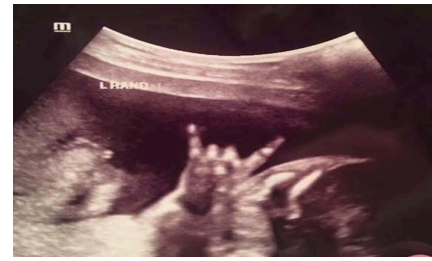

CASE RESOLUTION: Findings were consistent with large multilobar PNA w/ small



parapneumonic effusion. Within 10m of the US exam our pt was started on IV abx and admitted to the PICU. Over the next few days, the pt did not improve as expected. She had a chest tube placed for her effusion, which was positive for S. pneumo. After minimal drainage she received intrapleural fibrinolysis which facilitated adequate drainage. Pt improved and was discharged on hospital day 19. At 30 day follow up she was markedly improved.

Featured FOAM-US Resource



We love the spirit behind this new, crowd-sourced website. EverydayUltrasound.com allows students, residents and seasoned clinicians the opportunity to share their cases with the goal of inspiring others to use ultrasound to be better clinicians. Led by Mike Halperin, Director of Emergency Ultrasound Fellowship Program at Jacobi / Montefiore, this all-star team has put together a clean, simple, easy-to-navigate but effective site that allows visitors to hone their image interpretation and clinical integration skills

Everyday Ultrasound

LOCAL | GLOBAL

Everyday
Ultrasound

LOCAL | GLOBAL

Articles in Biliary

Wall Echo Shadow (WES): Amy Cameron and
Christina Cheng PA-C | Boston, MA

June 21, 2019 in Biliary

To ignite your curiosity to start, or continue learning point of care ultrasound.

Cases

Search

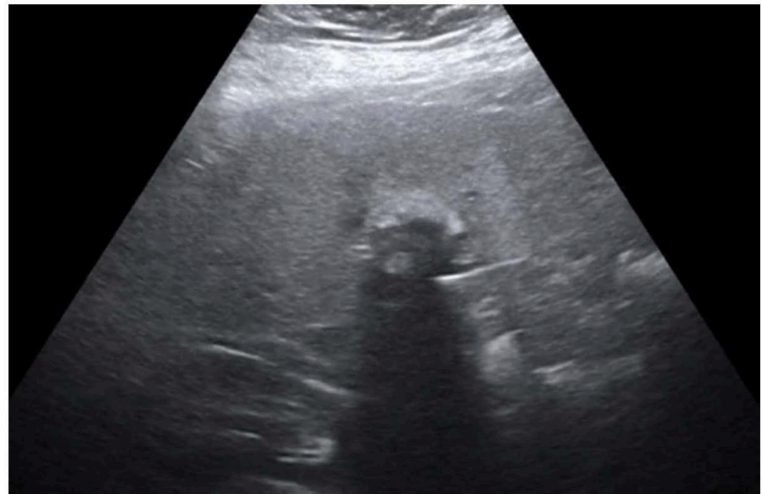
How to use

Mission

Team

Contribute | Email us

Disclaimer



A middle-aged F presents with epigastric abdominal pain radiating to her back. Symptoms for a month, but getting worse. Nausea, but no fevers or emesis. Noted to have epigastric discomfort,

UPCOMING US COURSES

Not intended as an exhaustive list but rather a list of courses SPOCUS members have found valuable.

3rd Rock Ultrasound (EM intro course)

November 15-16 • Las Vegas
December 6-7 • Charleston, SC

Bread & Butter Essentials Ultrasound Course

Stone Brewery, San Diego
February 11-13th, 2020

School of Medicine Ultrasound Institute University of South Carolina. Introduction to Primary Care US. Columbia, SC

December 5-6, 2019
January 23-24, 2020
March 19-20, 2020
May 21-22, 2020

Limited OB Ultrasound

- October 3-5, 2019
- January 9-11, 2020
- March 12-14, 2020
- June 11-13, 2020
- October 15-17, 2020

Philadelphia, PA
Sponsored by Thomas Jefferson University.

US for Primary Care Courses conducted by the Institute for International Medicine.

- **2019 Glendale CA, hosted by Glendale Adventist Medical Center**
- December 12, 2019 (Thu) in Glendale CA
- **2020 Kansas City, KS, hosted by University of Kansas Medical Center**
- June 4, 2020 (Thurs) in Kansas City, KS
- **2020 Fort Worth, TX, hosted by University of North Texas Health Science Center**
- June 10, 2020 (Wed) in Fort Worth, TX

Like us and connect with SPOCUS on social media where you can stay up to date on the latest workshop opportunities and catch great cases, the latest lit, and educational material from across the world wide

Web: <https://spocus.org/>

Email: spocus001@gmail.com

Twitter: @POCUS_Society

Facebook: Society of Point of Care Ultrasound

LinkedIn: Society of Point of Care Ultrasound

Our Partners

